

# An Augmented Magnetic Navigation System for Transcatheter Aortic Valve Implantation

Zhe Luo, Junfeng Cai, Yuanyuan Nie, Guotai Wang and Lixu Gu<sup>\*</sup>, *Senior Member, IEEE*

**Abstract**—This research proposes an augmented magnetic navigation system for Transcatheter Aortic Valve Implantation (TAVI) employing a magnetic tracking system (MTS) combined with a dynamic aortic model and intra-operative ultrasound (US) images. The dynamic 3D aortic model is constructed based on the preoperative 4D computed tomography (CT), which is animated according to the real time electrocardiograph (ECG) input of patient. And a preoperative planning is performed to determine the target position of the aortic valve prosthesis. The temporal alignment is performed to synchronize the ECG signals, intra-operative US image and tracking information. Afterwards, with the assistance of synchronized ECG signals, the contour of aortic root automatic extracted from short axis US image is registered to the dynamic aortic model by a feature based registration intra-operatively. Then the augmented MTS guides the interventionist to confidently position and deploy the aortic valve prosthesis to target. The system was validated by animal studies on three porcine subjects, the deployment and tilting errors of which are  $3.17 \pm 0.91\text{mm}$  and  $7.40 \pm 2.89^\circ$  respectively.

## I. INTRODUCTION

Aortic stenosis (AS) is the common disorder, whose pathology includes processes similar to those in atherosclerosis, including lipid accumulation, inflammation, and calcification [1]. It could result in a high rate of death, about 50% in the first 2 years after symptoms appearance, among the untreated patients [2]. Surgical replacement of the aortic valve is required to treat symptoms and improve survival in AS patient [3]. However many patients with symptomatic severe AS cannot undergo surgery valve replacement due to advanced age, or significant comorbidities [4]. Transcatheter aortic valve implantation (TAVI) is a new procedure and less invasive alternative to offer patients a less invasive alternative enabling valve replacement to be performed without the need for sternotomy, cardiopulmonary bypass [5]. Position of valve during the deployment is paramount and challenging to the procedural success to displace the native valve leaflets and deploy within the native valve annulus [6]. Fluoroscopy (contrast-enhanced fluoroscopy) is commonly used to visualize the aortic

anatomy and valve stent to position the target and guide TAVI [7], which has three distinct disadvantages: exposing the clinicians, staff and patient to ionizing radiation; increasing the risk of iatrogenic renal injury [8]; and poor visualization in some regions of the aorta giving rise to navigational limitations [9].

To provide better guidance for TAVI, some researchers have focused on the work using intra-operative 3D imaging including intra-operative computed tomography (CT) [10], magnetic resonance imaging (MRI) [11-12] and Ultrasound (US) [13]. However, the intra-operative CT still exposes the interventionists and patients to the radiation, and the high cost of the real time MRI and 3D US limits their applications in clinical settings. In additional, magnetic navigation system (MTS) is another possible alternative for cardiac intervention [14-15], the lack of utility intra-operative imaging of which makes the deployment accuracy compromise due to the movement of aortic valve. This paper proposes an MTS augmented by intra-operative US image registered to preoperative dynamic aortic model as an alternative means of guiding TAVI intra-operatively.

## II. METHOD

### A. Construct dynamic 3D aortic model

The dynamic aortic model is constructed based on the 4D CT image of the beating heart over a cardiac cycle with retrospective ECG gating. Ten 3D CT images, which are high resolution and enhanced by contrast agent injections, of the beating heart over the cardiac cycle, are acquired using a TOSHIBA Aquilion ONE CT with imaging parameters: slice thickness = 0.5mm, pitch = 0.237, kVp = 120, mA = 132, field of view = 22cm, image resolution = 512×512, and spacing=0.653mm×0.653mm×0.25mm. Due to minimal heart motion on a cardiac circle resulting in the image least susceptible to motion artefacts, the enddiastolic (ED) image of the 4D image is chosen to create a static model, where the aortic structure is segmented manually slice by slice. Then a marching cube algorithm [16] is employed to reconstruct the surface model of the aortic structure. Finally the dynamic aortic model consists of 10 surface static models.

### B. Preoperative planning

Prior to the surgery, the interventionist has to determine the optimal position of the prosthesis on the preoperative image. The structure of the prosthesis is shown in Fig. 1, which has three nadir leaflets. For each preoperative CT image, the interventionist identifies the three nadirs of the leaflets manually to determine the annular plane. Then translate the annular plane along its normal towards left ventricle (LV) with translation distance half of the height of the skirt (6mm in our application). The final plane is defined as the target position in the dynamic aortic model.

<sup>\*</sup>Corresponding Author

This research is supported by the Chinese NSFC research fund (61190120, 61190124 and 61271318), the Shanghai municipal health bureau research fund (2011216) and the Biomedical engineering fund of Shanghai Jiao Tong University (YG2012MS21).

Zhe Luo, Yuanyuan Nie, Guotai Wang and Lixu Gu are with the Image Guided Surgery and Therapy Laboratory, School of Biomedical Engineering, Shanghai Jiao Tong University, Shanghai 200030, China (e-mail:luozhe2007@sjtu.edu.cn).

Junfeng Cai is with the Department of Cardiac Surgery, Ruijin Hospital, Shanghai Jiao Tong University, Shanghai 200030, China (e-mail:lonlon\_cn@hotmail.com).

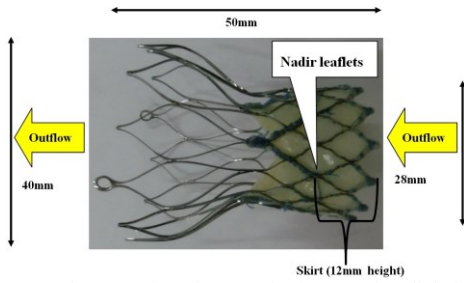


Fig. 1. The transcatheter aortic valve prosthesis. A pericardial skirt, which is designed to prevent paravalvular regurgitation, covers the lower segment of the aortic valve prosthesis from the inflow to the nadir of the leaflets

### C. Aortic root contour extraction

The aortic valve contour of short axis US image was segmented to be registered to the preoperative aortic model intra-operatively. A probability estimation based energy function [13] and graphic processing unit (GPU) accelerated continuous max-flow algorithm [17-18] was employed to automatically segment the aortic root contour from US image intra-operatively.

### D. Temporal Alignment

As shown in Fig. 2, there are two aspects involved in information acquisition synchronization. Firstly, owing to different sampling delay in US images, ECG signals and spatial tracking information acquisition, the readings from different inputs, even at the same time, may not be corresponding to the same cardiac phase. Secondly, the varied latency within the different data acquisition systems is the other aspect. The latency is the period between the commencement of data collection and when the data are reported to the processing system. The sampling delay of the spatial tracking information, which are  $4 \times 4$  matrixes containing the position and orientation information of sensors mounted on the cannula, catheter and the US probe respectively, is less than 0.1ms in our system. Therefore, we don't take the sample latency of spatial tracking information into account.

In this system, an ECG acquisition thread and a US image acquisition thread are created to acquire the ECG signals and US image in parallel. They are synchronized by a synchronization thread. The ECG acquisition thread acquires real-time ECG signals of subject from the ECG recorder through a serial port, analyzes the corresponding cardiac phase of current input ECG signal and write the cardiac phase to a public buffer about 62 times/second (about 16ms between two neighboring ECG signals sample). The US acquisition thread acquires a US image from US machine (the time-span of each acquisition is about 65ms). For each update time, after the synchronization thread obtained current cardiac phase

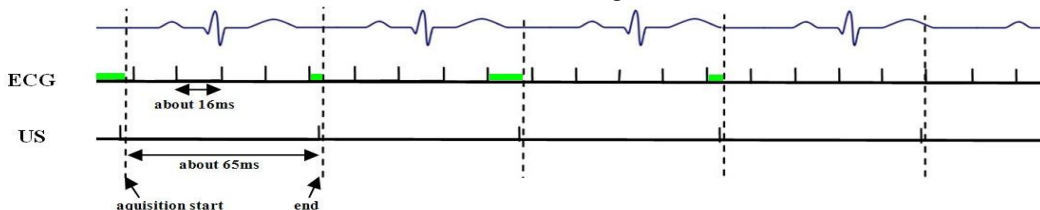


Fig. 2. Diagram of acquisition latency of US image. Besides the US image, the figure illustrates the sampling instants of ECG signals. For each US image, the former end point of the bold green line is the cardiac phase corresponding to it. The length of the green bold line is the error of this cardiac phase.

from public buffer and tracking information, it notifies the US image acquisition thread to obtain current US image. Fig. 2 shows that the error of the synchronization between the US image and its corresponding ECG signal is less than 16ms.

### E. Spatial Registration

The registration of the system consists of two steps, initial and intra-operative registration. The feature based algorithm we used is iterative closest points (ICP) [19] which is an iterative optimization problem. Good start point will accelerate the convergence and make it avoid local minima. The initial registration offers intra registration a good enough start point to convergent quickly. Fig. 3 shows one result of registration.

#### 1) Initial registration

We perform a rigid landmark-based registration that minimizes the mean-squared distance between homologous landmarks in the preoperative image and patient (world) to get an initial transform  $TM_{image \leftarrow world}$ . For the same reason described in section “Dynamic Aortic Model”, ED image of the preoperative images is chosen to be performed in this operation. Based on the temporal alignment between the US images and ECG signals acquisition, we get a series of US images of aortic root at short and long axis view with their cardiac phases. Each of the US images is corresponding to a preoperative aortic model according to its cardiac phase. In order to get better initial transform, every aortic model is corresponding to at least one US image of long axis view and one of short axis view. Then the contour of aortic root in each US is manually selected. The points of all contours are transformed to preoperative image coordinate using  $TM_{image \leftarrow world} * TM_{world \leftarrow US}$ . Thus we get 10 groups contours with their corresponding cardiac phases related to their aortic surface model. All the synchronized pairs of transformed aortic root contours and surface models are registered using ICP algorithm and get the transform  $TM_i$  ( $i=1, \dots, 10$ ). Thus for each preoperative aortic model, we have a transform  $TM'_i (= TM_i * TM_{image \leftarrow world})$  from the patient coordinate to the preoperative image coordinate, which is used as an initial transformation for intra-operative registration.

#### 2) Intra-operative registration

After initial registration finished, aortic root contour of each US image is registered to preoperative image (dynamic aortic model) intra-operatively. In each registration, input US image of short axis view is obtained with its corresponding

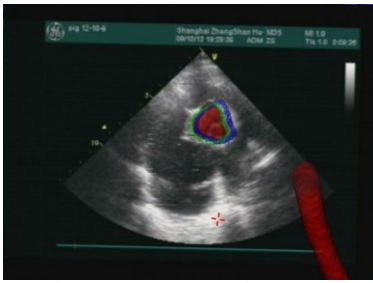

Fig. 3. Register the contour automatic extracted from US image intra-operatively to the preoperative dynamic aortic model. The blue point set is the points of the contour and the green point set is the result after the blue point set registered to the aortic model using ICP registration.

cardiac phase, following the system extracting the aortic contour of current image using method described in section “Aortic Root Contour Extraction”. Assume the cardiac phase of the contour is same as preoperative CT image  $i$ . The points of the contour are transformed by  $TM_i' * TM_{world \leftarrow US}$ . Then the transformed points of the contour is registered to the surface model  $i$  using ICP algorithm and get a new transform  $TM_i''$ . At last, the transform  $TM_i'' * TM_i'$  is used to update the transform in the system. This process is implanted in paralleled method.

#### F. Components

##### 1) Transcatheter aortic valve prosthesis

The transcatheter aortic valve prosthesis (MicroPort., Shanghai, China) we used is a self-expanding valve stent frame and composed of nitinol with porcine pericardial leaflets. It expands at normal temperature, but can be compressed in ice water to fit inside a catheter. Its components are demonstrated in Fig. 1.

##### 2) Catheter

A 18F catheter (MicroPort., Shanghai, China) is used to deliver the aortic valve prosthesis. Two 5D sensors are embedded in the front part of the catheter. The prosthesis is compressed and embedded into the catheter between the two sensors so that the MTS can track the position and orientation of the prosthesis when the catheter is inserted into the aorta.

##### 3) Tracking device

An Aurora MTS (North Digital., Waterloo, On, Canada) is employed to track the position and orientation of the catheter, the cannula and the US probe.

##### 4) Guide wire and cannula

Prior to the insertion of the catheter in which prosthesis is included, a guide wire is advanced from the common femoral artery access into the aortic root. The guide-wire is enclosed by a cannula in front of which four MTS sensors are embedded to enable tracking. The positions of these four sensors are used to fit a cardinal spline to create a model of front part of the cannula that can be displayed in the system, which makes the interventionist aware whether the cannula pass through the aortic arch or not. When the cannula arrives at the aortic root, it is extracted, while the guide wire remains. Then the catheter is inserted into the aorta along the guide wire until it arrived at the aortic root.

##### 5) ECG reading device

A handled ECG reader device (Beijing Choice Electronic Tech, Beijing, China) is used to sample cardiac phase of subject intra-operatively.

##### 6) Software

We developed the software using Python 2.7, and makes extensive use of classes from free visualization toolkit: VTK 5.6 ([www.vtk.org](http://www.vtk.org)), Atamai ([www.atamai.com](http://www.atamai.com)) and Compute Unified Device Architecture (CUDA 4.0). It runs under Windows XP, on an Intel Core i5 computer with NVIDIA GeForce GTX 460 graphics card. A GE Vivid 7 US machine is used to obtain the US image.

#### G. Validation

The system was validated by three porcine studies which measured two errors and performed prosthesis deployment.

##### 1) Deployment Distance Error (DDE)

DDE is defined as the difference between actual final prosthesis position and its target position defined by preoperative planning. It is measured as the distance between the leading edge of the prosthesis to the target plane in the post-operative CT coordinate system.

##### 2) Deployment Tilting Error (DTE)

DTE is defined to evaluate how well the system can help to position the valve in the aortic root anatomy with a correct tilting [20]. It is measured as the angle between the target plane normal and normal of the plane defined by the leading edge of the prosthesis in the post-operative CT coordinate system.

### III. RESULT

In each case, the DDE and DTE were employed to calculate the final errors.

The details of the experiment are as follows.

Pigs weighing between 70-80kg were selected for the experiments. Eight fiducial landmarks, which are ECG electrodes, were attached on the skin in the area of the rib-cage. The animals were anaesthetized and the heart rate was reduced to 90-100 beats/min by injected Betaloc (5mg:5ml, Vetter Pharma-Fertigung GmbH & CoKG, Germany) during the procedure. Respiration was controlled by a mechanical ventilator at 15-20 cycles/min.

The preoperative dynamic aortic model of the animal was reconstructed using the method described earlier and then imported into the navigation system. Preoperative planning was performed on the model and the target position of prosthesis was determined.

Finally, the registration described above was performed to the fused real time US image with preoperative dynamic aortic model. Then the tracked guide wire was advanced from the common femoral artery access to the aortic root. When the cannula arrived at the aortic root along with the guide wire, the former was removed. Afterwards the catheter entered the aorta along the guide wire. Under the guidance of the augmented MTS as shown in Fig. 4, the interventionists was able to confidently locate the target position and release the transcatheter valve prosthesis to the target position. After the

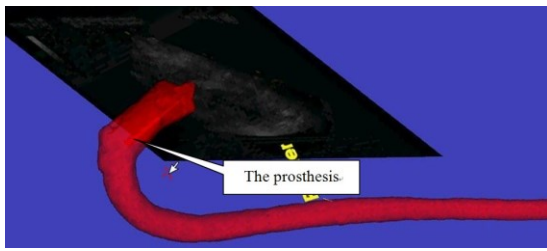


Fig. 4. The guidance of system.

operation, the postoperative CT image was examined to determine the DDE and DTE.

The DDE and DTE are  $3.17 \pm 0.91$  mm and  $7.40 \pm 2.89^\circ$  respectively as shown in Fig. 5. The DDE of less than 4mm that we achieved can be considered as a clinically acceptable result. The average DDE of standard fluoroscopic guidance is around 5mm when our approach achieved  $3.23 \pm 0.94$ mm. For the DTE,  $0.0^\circ$ - $5.0^\circ$  is considered as very good,  $5.0^\circ$ - $10.0^\circ$  as good,  $10.0^\circ$ - $15.0^\circ$  as acceptable, and larger than  $15.0^\circ$  as inappropriate [20]. The DTE of our study is  $7.40 \pm 2.89^\circ$  (two

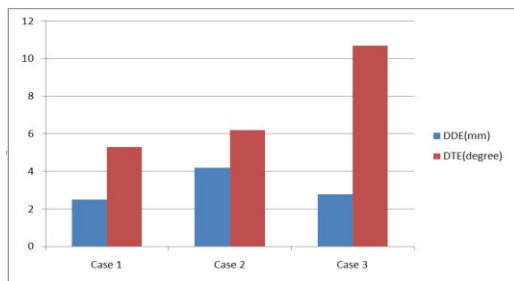


Fig. 5. The results of animal study.

less than  $10.0^\circ$  and one less than  $15.0^\circ$ ).

#### IV. CONCLUSION

This paper proposed an augmented MTS for transcatheter aortic prosthesis deployment using intra-operative US imaging and dynamic aortic model. The animal study results reveal that this method is another possible option for delivery and deployment of an aortic prosthesis.

#### ACKNOWLEDGMENT

The authors are grateful to the radiologists from Zhongshan Hospital for their support in animal imaging and animal surgery as well as to MicroPort Co., Ltd. for providing and renewing cannula, transcatheter and aortic valve prosthesis for MTS guidance purpose.

#### REFERENCES

- [1] CM Otto, J Knuusisto, DD Reichenbach, AM Gown, KD O'Brien, "Characterization of the early lesion of "degenerative" valvular aortic stenosis. Histological and immunohistochemical studies," *Circulation*, vol. 90, issue. 2, pp. 844-853, 1994.
- [2] MB Leon, CR Smith, M Mack, DC Miller, JW Moses, LG Svensson, EM Tuzcu, JG Webb, GP Fontana, RR Makkar, DL Brown, PC Block, RA Guyton, AD Pichard, JE Bavaria, HC Herrmann, PS Douglas, JL Petersen, JJ Akin, WN Anderson, D Wang, S Pocock, "Transcatheter aortic-valve implantation for aortic stenosis in patients who cannot undergo surgery," *N Engl J Med*, 363(17):1597-607, 2010.

- [3] R Bonow, B Carabello, K Chatterjee, AC de Leon, Jr., DP Faxon, MD Freed, WH Gaasch, BW Lytle, RA Nishimura, PT O'Gara, RA O'Rourke, CM Otto, PM Shah, and JS Shanewise, "Focused update incorporated into the acc/aha 2006 guidelines for the management of patients with valvular heart disease: a report of the American college of cardiology/American heart association task force on practice guidelines," *Circulation*, vol. 118, pp. e523-e661, 2008.
- [4] B. lung, A Cachier, G Baron, D Messika-Zeitoun, F Delahaye, P Tornos, CG Arwolf, E Boersma, P Ravaud, and A Vahanian, "Decisionmaking in elderly patients with severe aortic stenosis: Why are so many denied surgery?," *Eur. Heart J.*, vol. 26, pp. 2714-2720, 2005.
- [5] M Chu, M Borger, F Mohr, and T Walther, "Transcatheter heart-valve replacement: Update," *Can. Med. Assoc. J.*, vol. 182, no. 8, pp. 791-795, 2010.
- [6] J Leipsic, R Guvitch, T LaBounty, J Min, D Wood, M Johnson, A Ajlan, N Wijesinghe, J Webb, "Multidetector Computed Tomography in Transcatheter Aortic Valve Implantation," *J Am Coll Cardiol Img.*, vol. 4, issue. 4, pp.416-429, 2011.
- [7] V Delgado, A Ng, M Shanks, F Van Der Kley, J Schuijff, N Van De Veire, L Kroft, A Roos, M Schaliq, and J Bax, "Transcatheter aortic valve implantation: Role of multimodality cardiac imaging," *Expert Rev. Cardiovasc. Ther.*, vol. 8, no. 1, pp. 113-123, 2010.
- [8] T Darwish, "An evidence-based approach to minimise contrast-induced neuropathy," *N Z Med J*, vol. 122, pp. 39-41, July. 2009.
- [9] RK Greenberg, S Haulon, S O'Neill, S Lyden, KOuriel, "Primary endovascular repair of juxtarenal aneurysms with fenestrated endovascular grafting," *Eur J Vasc Endovasc Surg*, vol. 27, pp. 484-491, May. 2004.
- [10] J Kempfert, A Rastan, A Noetling, J Blumenstein, A Linke, F Schule, G Mohr, and T Walther, "Perioperative dynact for improved imaging during transapical aortic valve implantation," *Circulation*, vol. 122, no. 21S, Nov. 2010.
- [11] K Horvath, D Mazilu, M Guttman, A Zetts, T Hunt, and M Li, "Midterm results of transapical aortic valve replacement via real-time magnetic resonance imaging guidance," *J. Thoracic Cardiovasc. Surg.*, vol. 139, no. 2, pp. 424-430, 2010.
- [12] K Horvath, D Mazilu, O Kocaturk, and M Li, "Transapical aortic valve replacement under real-time magnetic resonance imaging guidance: Experimental results with balloon-expandable and self-expanding stents," *Eur. J. Cardio-Thoracic Surg.*, vol. 39, no. 6, pp. 822-828, 2011.
- [13] P Lang, M Rajchl, AJ McLeod, MW Chu and TM Peters, "Feature Identification for Image-Guided Transcatheter Aortic Valve Implantation," in *Proc.SPIE Med. Imag. Conf.*, vol.8316, pp.83162X-83162X-14, 2011.
- [14] N Abi-Jaoudeh, N Glossop, M Dake, WF Pritchard, A Chiesa, MR Dreher, T Tang, JW Karanian and BJ Wood, "Electromagnetic Navigation for Thoracic Aortic Stent-graft Deployment: A Pilot Study in Swine," *J Vasc Interv Radiol*, vol. 21, issue. 6, pp. 888-895, 2010.
- [15] Z Luo, JF Cai, S Wang, Q Zhao, TM Peters and L Gu, "Magnetic Navigation for Thoracic Aortic Stent-graft Deployment using Ultrasound Image Guidance," *IEEE Transactions on Biomedical Engineering*, 2012, 10.1109/TBME.2012.2206388.
- [16] WE Lorensen, HE Cline, "Marching Cubes: A high resolution 3D surface construction algorithm," *Computer Graphics (Proc. SIGGRAPH)*, vol. 21, issue. 4, pp. 163-169, 1987.
- [17] J Yuan, E Bae, and XC Tai, "A study on continuous max-flow and min-cut approaches," *IEEE Computer Society Conference on Computer Vision and Pattern Recognition*, pp. 2217-2224, 2010.
- [18] M Rajchl, J Yuan, E Ukwatta and TM Peters, "Fast interactive multi-region cardiac segmentation with linearly ordered labels," In: *International Symposium on Biomedical Imaging (ISBI), International Conference on IEEE*, 2012.
- [19] P Besl and N McKay, "A Method for Registration of 3-D Shapes", *IEEE Trans. Pattern Analysis and Machine Intelligence*, vol. 14, no. 2, pp. 239-256, 1992.
- [20] M John, R Liao, YF Zheng, A Nöttling, J Boese, U Kirschstein, J Kempfert and T Walther, "System to Guide Transcatheter Aortic Valve Implantations Based on Interventional C-Arm CT Imaging," *MICCAI 2010*, vol. 6361, pp. 375-382, 2010.