

Non-Invasive Evaluation of Opening and Closing Timings of the Cardiac Valves in the Fetal Cardiac Cycle

AH Khandoker¹, Y Kimura², T Ito², N Sato²,
K Okamura², M Palaniswami¹

¹The University of Melbourne, Victoria, Australia

²Tohoku University, Sendai, Japan

Abstract

In this study, we propose a non-invasive system to recognize the timings of fetal cardiac events on the basis of analysis of fetal ECG and Doppler ultrasound signal together. Fetal ECG was extracted from transabdominal ECG (10 normal subjects, 38-41 weeks of gestation) using blind source separation with the reference signal. Multiresolution wavelet analysis enabled the frequency contents of the Doppler signals to be linked to the opening(o) and closing(c) of the heart's valves (Aortic (A) and mitral(M)). M-mode, B-mode and pulsed Doppler ultrasound were used to examine and verify the timings of opening and closure of aortic as well as mitral valves. The time intervals from Q-wave of QRS complex of fetal ECG to opening and closing of aortic valve, i.e. Q-Ao and Q-Ac were found to be 75.0 ± 11.9 (msec) and 221.6 ± 29.0 (msec) respectively. As for the mitral valve, Q-Mc and Q-Mo were found to be 45.0 ± 18.9 (msec) and 301.6 ± 20.7 (msec) respectively.

1. Introduction

Evaluation of fetal cardiac activity received limited attention for research. It is known that congenital heart defects (CHD) and foetal distress (e.g. low oxygen levels in fetus) are the most common major causes of congenital abnormalities and foetal mortality. The prevalence is 3–8 per 1000 pregnancies at birth [1]. Studies have shown that an early detection of some fetuses with potentially ductal-dependent CHD results in an improvement of hemodynamic status, neonatal morbidity and surgical outcome [2].

Long QT syndrome is one of the prevalent CHDs characterized by the presence of a prolonged QT interval on electrocardiography (ECG) and a high risk for developing life-threatening arrhythmias and sudden cardiac death in children and adults [3]. There have been two reports describing prenatal cardiotocographic

findings in fetuses with long QT syndrome [4-5]. However, to our knowledge, definitive prenatal diagnosis of this congenital syndrome has not been described.

Maternal risk factors and a large number of intrapartum causes lead to foetal hypoxia. Diagnostics of distressed unborn baby is mainly aimed at detection of occurrence of intrauterine hypoxia. Consequences resulting from foetal hypoxia appear in its heart activity [6]. In perinatal medicine, non-invasive cardiotocography (CTG) which is a record of the foetal heart rate (FHR) and uterine contraction activity measured from a transducer on the abdomen is commonly used. Sometimes abnormal variability in fetal heart rate may not necessarily represent the fetus in distress.

The systolic time intervals (STI) of the fetal cardiac cycle have been analyzed by several authors in the past. The pre-ejection period (PEP) and left ventricular ejection time (VET) are reported to be sensitive markers of fetal cardiac performance [7]. PEP which is defined as the interval between the onset of the QRS complex of fetal ECG and the start of ventricular ejection (i.e., the opening of aortic valve), is known to be a sensitive indicator of myocardial performance [9]. VET is the time interval from opening to closure of semilunar or aortic valve, during which blood is flowing from ventricle into outflow. There is a method that uses systolic time interval (STI) which can be calculated with an invasively measured fetal electrocardiogram (FECG) via scalp electrodes and a Doppler shift of ultrasound beam reflected from moving valves of fetal heart. Even though it can provide high diagnostic sensitivity, it can not be applied until the occurrence of uterine rupture.

A new research paradigm is, therefore, required to address the above mentioned issues. In this study, for better diagnosing fetus prenatally, we propose and validate a novel non-invasive system to recognize the timings of fetal cardiac events on the basis of analysis of electrical (fetal ECG) and mechanical (Doppler ultrasound (DUS) signals) heart activity together.

2. Methods

Simultaneous recording of the abdominal ECG signals and Doppler ultrasound signals from ten mothers at the gestational age of 38~41 weeks were collected from Tohoku University Biomedical Engineering Research Organization (TUBERO) database. A total of 10 recordings (10 minutes length) were sampled at 1KHz with 16-bit resolution.

The Doppler ultrasound (DUS) data were obtained using Ultrasonic Transducer 5700 (fetal monitor 116, Corometrics Medical Systems Inc.) with 1.15 MHz signals. To compare the actual appearance of aortic valve's opening and closing pattern with valve timing events appeared in DUS signals, M-mode, B-mode and pulsed-wave Doppler signals were obtained from convex 3.5Hz of HITACHI ultrasound scanner (Ultrasonic diagnostic instrument Model EUB-525; HITACHI health medical corporation). The detailed procedure for experimental set up and transabdominal ECG data collection has been described in our previous study [8]. FECG traces were extracted from using a method that combines cancellation of the mother's ECG signal and the Blind source separation with reference (BSSR) as described in our earlier study [8]. Briefly, the cancellation of the mother's ECG component was performed by subtracting the linear combination of mutually orthogonal projections of the heart vector. Doppler ultrasound signal was taken as reference signal.

3. Results and discussion

3.1. Timings of valve motions in fetal cardiac cycle

From extensive studies of the heart's physiology that have already been performed the prominent cardiac motions that occur can be deduced. These are due to cardiac wall movement and valve movement. Atrial contraction is initiated by the P wave while ventricular contraction is related to R wave activity, hence significant content in the ultrasound signal may be expected at these times. Since both sides of the heart are in synchrony and due to the simultaneous operation of the pulmonic and aortic valves and the tricuspid and mitral (atrioventricular) valves, their individual activity cannot be expected to appear itself in the ultrasound signal. Fig. 1 shows the relative opening and closing timings of the heart's aortic and mitral valves in relation to the FECG. Doppler frequency shifts associated with cardiac activity

can be visualized. Doppler ultrasound signals vary in time, this being due primarily to variations in the relative orientation of the fetal heart and the ultrasound transducer [7]. Therefore, all timing events of cardiac valves are unlikely to be distinguished in each cardiac cycle. Obviously fetal movement greatly affects the received signal.

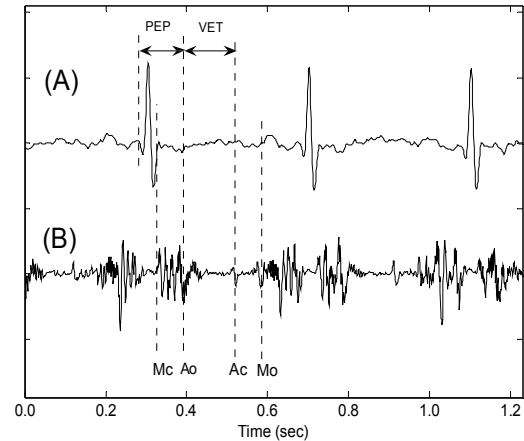


Figure 1. Example of simultaneously recorded fetal ECG and Doppler ultrasound (DUS) data. (A) foetal ECG signal extracted from maternal abdominal signals using Blind source separation with reference (BSSR) [8]. (B) Data from the nondirectional channel of the ultrasound from fetal heart. Annotations showing the timings of the opening and closing of the heart's aortic and mitral valves in relation to the electrocardiogram. Aortic (A), Mitral (M), opening (o), closing (c). PEP=pre-ejection period; VET= left ventricular ejection time.

3.2. Wavelet analysis of DUS signals

Interpretation of DUS signals in relation to cardiac motions and valve movements would be difficult unless time frequency analysis was not used. Wavelet analysis has become a powerful tool for analysis of nonstationary signals whose spectral characteristics change significantly over time. A wavelet transform uses a set of basis functions to decompose a signal into the detailed signals and the approximate signals of the original signal. Complex gaussian with order 2 was used as mother wavelet in this study.

Fig. 2 shows the use of M-mode, B-mode and pulsed Doppler ultrasound to examine the opening and closing timings of the aortic valve. M-mode is a useful adjunct to the fetal cardiovascular examination because it enables the physician to obtain the exact measurement of valve's structure. Pulsed Doppler examination demonstrates the

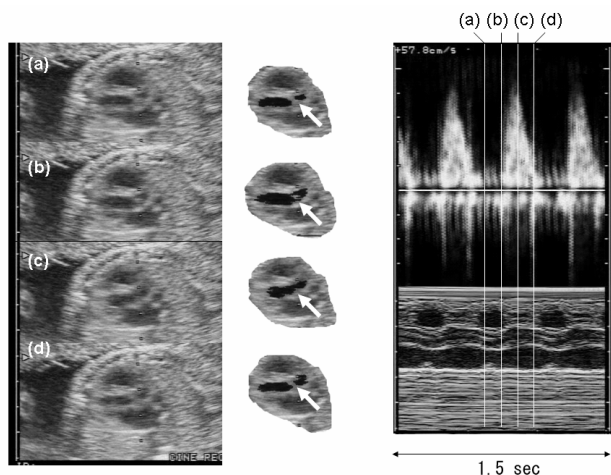


Figure 2. Left panels show B-mode views of a fetal aortic valve movements. The middle panels are the images extracted from B-mode views. White arrows show the aortic valve. Panel (a) shows the closing of the aortic valve, (b) shows the start of opening of the aortic valve, (c) shows that aortic valve is open and (d) shows that aortic valve is closed. The right panels show the Pulsed-wave Doppler signals during the opening and closing time of the aortic valve and its M-mode image at the same time phases.

direction and the characteristics of blood flow within the heart. The aortic blood flow Doppler waveform was recorded from the long axis of the five-chamber view of the heart. M-mode cursor was placed perpendicular to the inter-ventricular septum at the level of the mitral valve to examine end-systole and end-diastole (closure of atrioventricular valves).

Fig. 3&4 show two examples of the FECCG for several cardiac cycles together with DUS signals and its details signals at level 2 wavelet decomposition. The timings of aortic valve motions (in Fig. 3) and mitral valve motions (in Fig. 4) with respect to the ECG, the origin of the events highlighted within the DUS were elucidated and verified by pulsed Doppler ultrasound in the top panel. In order to detect the peak timings of aortic valve's motion events, the time durations from R wave within each RR interval chosen for each event were 0.05~0.10 sec for Ao and 0.14~0.26 sec for Ac. On the other hand, for mitral valve's relative timings, 0.00~0.05 sec for Mc and 0.26~0.33 sec for Mo were used in calculation. Although the QT interval can be obtained following delivery using ECG, this is not feasible in utero. The electromechanical Q-Ac interval which is measured from the onset of Q-wave to aortic valve closing, represent QT intervals which can be corrected for heart rate.

Table 1 shows analysis results presented as the mean duration of the aortic valve's opening and closing events

from the onset of Q wave of FECCG namely Q-Ao and Q-Ac within each RR interval.

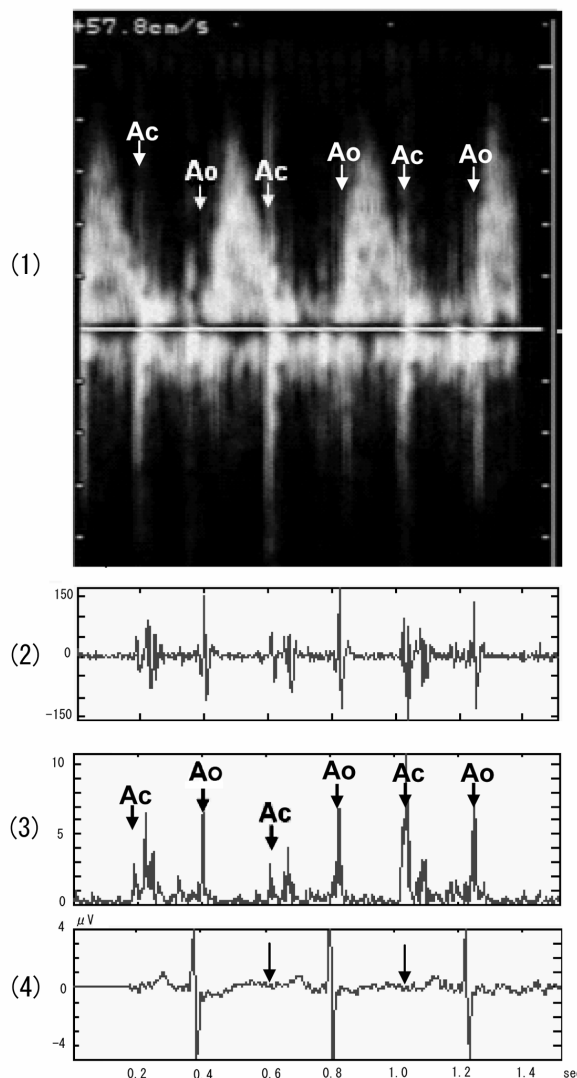


Figure 3. Upper panel (1) shows the example of Pulsed-wave Doppler signals of fetal aortic valve movements annotated to show how the specific signals are linked with opening and closing events. Ao and Ac represent the opening and closing of aortic valve. The lower panels show Doppler signals and its wavelet decomposition at level 2. Panel (2) shows the Doppler signals from fetal monitor 116. (3) shows the wavelet decomposition of Doppler signals at level 2. (4) shows the simultaneous fetal electrocardiogram signals.

There were cases where all events could easily be recognized. However, there were also cases where only particular events were observed. PEP(=75.0±11.9 msec) duration was not found to be influenced by heart rate

variation. However, VET ($=153.2\pm 18.9$ msec) was found to be inversely correlated with heart rate as reported by other studies on VET [7].

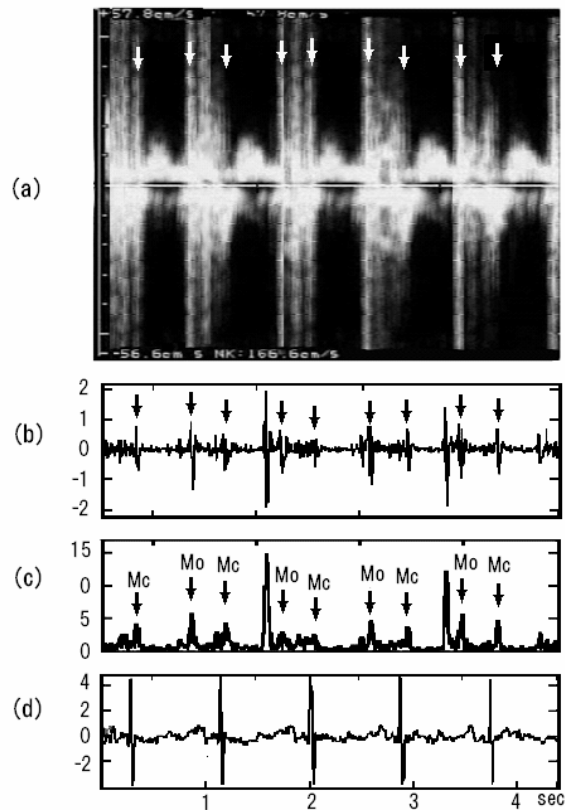


Figure 4. Upper panel (a) shows the example of Pulsed-wave Doppler signals of fetal mitral valve movements annotated to show how the specific signals are linked with opening and closing events. Mo and Mc represent the opening and closing of mitral valve. The lower panels show Doppler signals and its wavelet decomposition at level 2. Panel (b) shows the Doppler signals from fetal monitor 116. (c) shows the wavelet decomposition of Doppler signals at level 2. (d) shows the simultaneous fetal electrocardiogram signals.

Table 1: Summary of time intervals of opening and closing of the aortic and mitral valves from FECG over each cardiac cycle. Mean R-R intervals [403.6 ± 17.8 msec (N=680)].

	Q-Mc	Q-Ao	Q-Ac	Q-Mo
Mean (msec)	45.0	75.0	221.6	301.6
SD	18.9	11.9	29.0	20.7

4. Conclusions

Fetal ECG and Doppler ultrasound signals provide clinically significant information concerning the physiological state of a fetus. Multiresolution wavelet analysis enabled the frequency contents of the Doppler signals to be linked to the opening and closing of the aortic and mitral valves as confirmed by M-mode and pulsed Doppler. These results suggest means by which the cardiac events that contribute to the Doppler signal may be distinguished, providing information for better recognizing the fetal arrhythmia, anoxia and heart failure.

Acknowledgements

This study was supported by an Early career researcher (ECR) grant awarded to AH Khandoker by University of Melbourne. Additionally, partial supports were received from Australian Research Council (ARC) Intelligent sensing, sensor networks and information processing (ISSNIP) research network.

References

- [1] Ferencz C, Rubin JD, McCarter RJ. Congenital heart disease: prevalence at live birth. The Baltimore-Washington infant study. *Am J Epidemiol* 1985;121: 31–6
- [2] Bonnet D, Coltri A, Butera G, et al. Detection of transposition of the great arteries in fetuses reduces neonatal morbidity and mortality. *Circulation* 1999; 99:916–8
- [3] Schwartz PJ. The long QT syndrome. *Curr Probl Cardiol* 1997;22: 297–351.
- [4] Vigliani M. Romano–Ward syndrome diagnosed as moderate fetal bradycardia: a case report. *J Reprod Med.* 1995; 40: 725–728
- [5] Hofbeck M, Ulmer H, Beinder E, Sieber E, Singer H. Prenatal findings in patients with prolonged QT interval in the neonatal period. *Heart.*1997; 77: 198–204.
- [6] Matonia A, Jezewski J, Kupka T, Wrobel J, Horoba K, Widera M. Instrumentation for Fetal Cardiac Performance Analysis During the Antepartum Period. Proceedings of the IEEE Engineering in Medicine and Biology 27th Annual Conference, NY,2005; 1-4.
- [7] Murata Y and Martin, C. B. Systolic time intervals of the fetal cardiac cycle, *Obstet. Gynecol.*,1974; 44: 224-232
- [8] Sato M, Kimura Y, Chida S., Ito T, Katayama N, Okamura K., Nakao M. A Novel Extraction Method of Fetal Electrocardiogram From the Composite Abdominal Signal. *IEEE Trans on Biomed Engg.*, 2007; 54 (1): 49-58.
- [9] Goodlin R.C., Girard J., Hollmen A. “Systolic time intervals in the fetus and neonate”, *Circulation*, 1968; 37: 149-159.

Address for correspondence

Ahsan Khandoker

Dept. of Electrical & Electronic Engg. The University of Melbourne, VIC -3010, Australia.

E-mail: a.khandoker@ee.unimelb.edu.edu.au