

# Improving Image Integration: Comparison of Intra Cardiac Echocardiography Guided Surface Registration with Landmarks Registration

S Indiani, A Rossillo, A Bonso, S Themistoclakis,  
A Corrado, A Raviele

Ospedale dell'Angelo, Mestre Venezia, Italy

## Abstract

*In cardiac ablation, image integration can simplify the procedure, reduce complications and minimize radiation exposure. To achieve these results, the accuracy of the image integration process is crucial. In the present study, we compared ICE (intra-cardiac echocardiography)-guided landmarks registration with a new technique of ICE-guided localized surface registration. Twenty patients underwent registration by means of landmarks collected under ICE guidance (Group A). Twenty matched patients underwent the new localized ICE-guided surface registration, which involves collecting a single landmark in the inferior portion of the LIPV (left inferior pulmonary vein) and some surface points in the posterior area of the left PV antrum and around the antrum of the right PVs (Group B). In group A, the mean landmark error was  $4.62 \pm 1.65$  mm and the mean ablation-point error was  $3.00 \pm 0.99$  mm. In group B, the mean error between ECHO-guided surface points and MRI/CT surface was  $1.39 \pm 0.31$  mm and the mean ablation-point error was  $1.73 \pm 0.29$  mm. The quality of the final alignment was validated by means of ICE in both groups. Mathematical results combined with ICE-guided validation revealed that ICE-guided surface registration appears to offer better performance than landmarks registration.*

## 1. Introduction

CT/MRI image integration techniques in cardiac ablation are used increasingly often, particularly in pulmonary vein isolation for the treatment of atrial fibrillation. This approach provides very good anatomical detail and immediate identification of the ablator tip inside the cardiac chamber [1,2].

This method simplifies the ablation procedure, reduces complications and minimizes the exposure of both patient and operator to radiation [3,4].

The success of these techniques is heavily dependent

on good synchronization between the electroanatomic map and the 3D (CT/MRI) image [5]. There are two standard approaches to performing the registration process using the Carto Merge system (Biosense Webster):

- *Surface*: the left atrium (LA) is reconstructed by mapping the whole chamber by collecting points (electroanatomic map) and the registration process is then performed by fusing the 3D CT/MRI image and the electroanatomic map [2].
- *Landmarks*: some predefined points on the electroanatomic mapping system are acquired under both ICE and fluoroscopy guidance. The corresponding points are identified on the 3D CT/MRI scan image. The registration process is then executed [6].

The first method involves the risk of left atrial wall deformation due to the pressure of the mapping catheter on mobile regions [6]. The second does not guarantee a good global fit and is dependent on the operator's interpretation [10]. The aim of this study was to compare a new registration strategy, "local ICE-guided surface registration", with the landmarks registration technique.

## 2. Methods

### *Patient Population and Image Processing*

ICE-guided pulmonary vein antrum isolation by means of the Carto XP + Merge technology (Biosense Webster) was performed in 40 consecutive patients to treat symptomatic drug-refractory atrial fibrillation. Patient characteristics are shown in tables 1 and 2.

In order to define left atrial and pulmonary vein anatomy and to integrate this into the Carto XP technology, all patients underwent multi-slice detector CT scan (LightSpeed VCT GE Medical System). Before the ablation procedure, raw CT data were inserted into the Carto XP Image Integration module, the pulmonary veins and left atrium being separated from the surrounding structures. The images obtained were imported into the real-time mapping system for

registration. Patients were divided into two groups according to the registration strategy used. In 20 patients, registration used posterior landmarks, as described by Fahmy [6] (Group A). These patients were compared with another 20 patients matched for type of atrial fibrillation, AF duration, LA diameter, heart disease and LVEF, in whom the local ICE surface registration technique was used (Group B).

	Group A	Group B	P value
Age [y]	56 ± 15	60 ± 9	0.35
LA [mm]	40 ± 7	41 ± 6	0.84
LVEF [%]	57 ± 6	59 ± 3	0.33
AF duration [months]	57 ± 37	68 ± 61	0.49

	Group A	Group B	P value
Male gender	11	15	0.04
Paroxysmal AF	9	9	-
Persistent AF	5	5	-
Permanent AF	6	6	-

Tables 1 and 2. Patient characteristics in groups A and B.

### Landmarks registration

Landmarks registration was performed by acquiring some predefined points at the posterior wall close to the PV antra, as previously described. The corresponding points were identified on the 3-D CT image and the registration process was carried out.

### Local ICE-guided surface registration

A landmark point acquired at the inferior border of the LIPV ostium under ICE and fluoroscopic guidance (Figure 1) was inserted into the CT image. Another 7 – 12 points were acquired under ICE guidance at the posterior wall of the left PV antrum, where ablation was to be performed. The anterior side of LPVs was avoided, in order to obviate the potential difficulty of discerning the position of the ablation catheter tip in relation to the vein and the left atrial appendage. In addition, it may be difficult to keep the ablation catheter in a stable position on this ridge. For each right PV, 4 – 7 points were acquired at the possible ablation site in both the posterior and septal walls. No points were acquired in other areas (Table 3). As the points were acquired, care was taken to maintain perpendicular contact between the catheter tip and the endocardial tissue. Once a good atrial signal was obtained from the ablation catheter, the surface points were acquired and registration was performed. Figure 2 shows the area of the registration points.

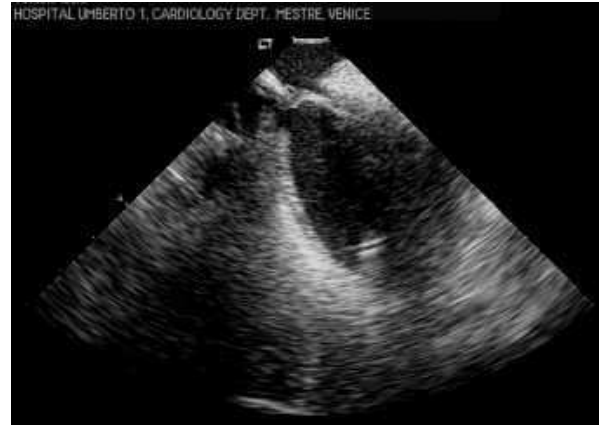

Figure 1. ICE image of the catheter tip at the LIPV ostium.

Map points (#)	LPV	RSPV	RIPV
20 ± 2	9 ± 1	5 ± 1	6 ± 1

Table 3. Distribution of points in the areas of interest.

### Registration Algorithm

Given that the patient undergoes CT/MRI and the ablation procedure in the same position, and that the assigned landmark guides the CT/MRI surface in the same plane as the anatomic map (visual alignment step), the CartoMerge registration software uses an iterative progression to provide a registration solution: the nearest local minimum to the initial spatial position [14]. Several studies have demonstrated that the square mean of distances of the points from surface, of the local minimum provided as a solution by the CartoMerge algorithm, is close to the value yielded by the global minimum [12,13].

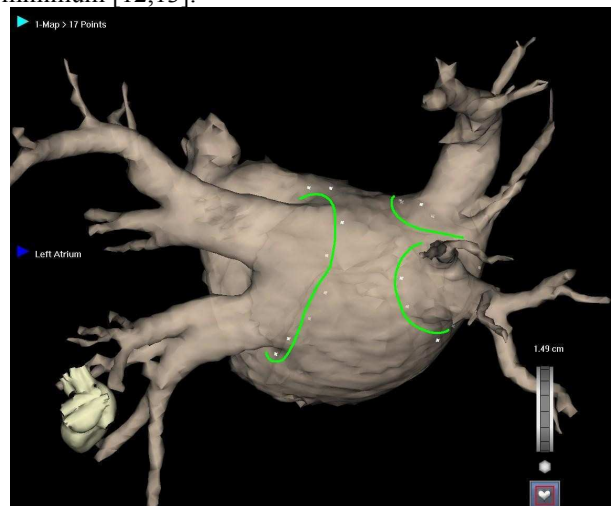


Figure 2. LA posterior view. The green lines show the areas of the registration points.

### Navigation phase and validation of registration

After registration, the quality of alignment of specific areas was assessed in both groups by means of ICE. This was done through ICE evaluation of the ability to reach the carina between the left PVs, the carina between the left PV and the LAA, and all the PVs by means of the CT map alone. Each ICE-confirmed area was regarded as one point. If four or fewer points were obtained, the registration process was repeated.

The mean landmark error (the distance between the point acquired under ICE guidance and the corresponding point on the CT surface image, provided by the physician), the mean surface error (the distance between acquired points and CT image) and the mean ablation error (the distance between ablation points acquired and CT image) were automatically calculated for each patient by a software feature of the Carto XP system. This last parameter, the mean ablation error, was considered a marker of alignment in both groups.

### PVAI ablation procedure

To achieve pulmonary vein antrum isolation, we used a circular catheter (Lasso Biosense Webster, Inc) and a 3.5 mm tip thermocool catheter (Biosense Webster, Inc) to ablate at the antrum of the pulmonary vein until isolation and disappearance of all PV potentials were obtained. RF power was set at 30W in a power-controlled mode and titrated up to 40W, with a temperature limit of 42°C. This technique has been described in detail elsewhere [7]. To acquire ablation points, which were used as markers of alignment, both of the following conditions were met:

- Electrical contact: the catheter tip detected the electrical signal before ablation started; consequently, it showed the voltage amplitude reduction during delivery;
- Real visual contact: the catheter tip was visualized in contact with the endocardial tissue in the real-time ICE image; alternatively, it was visualized under fluoroscopy in contact with the Lasso catheter, which was placed on the ostium of the vein.

### Statistical Analysis

Continuous variables are expressed as mean±SD. Continuous variables were compared by means of Student's t and the Mann-Whitney test. Categorical variables were compared by Chi-square analysis or Fisher's exact test. Correlations were drawn between landmark and surface points by using Pearson's correlation coefficient. Results with  $P < 0.05$  were considered statistically significant.

## 3. Results

In group A, the mean landmark error was  $4.62 \pm 1.65$  mm and the mean ablation-point error was  $3.00 \pm 1.65$

mm. No correlation was found (0.19) between the two errors; consequently, a landmark synchronization that displays a low mean error is not necessarily a good registration (Figure 3). In group B, the mean surface error was  $1.39 \pm 0.31$  mm and the mean ablation-point error was  $1.79 \pm 0.28$  mm. A strong correlation was found between the two errors (0.75); therefore, when local ICE-guided surface registration is used, a small error implies good synchronization (Figure 4).

The navigation score was lower than 4 points in 6 group A patients and 1 group B patient ( $p=0.05$ ), as expected. The good performance of the proposed method is also shown by the duration of the phases of the procedure; procedure time, fluoroscopy time and registration-phase time were:  $251 \pm 48$  min,  $79 \pm 24$  min and  $24 \pm 2$  min, respectively, in group A, and  $203 \pm 3$  min,  $59 \pm 16$  min,  $15 \pm 2$ , respectively, in group B ( $p < 0.01$ ,  $p=0.03$ ,  $p < 0.01$ ).

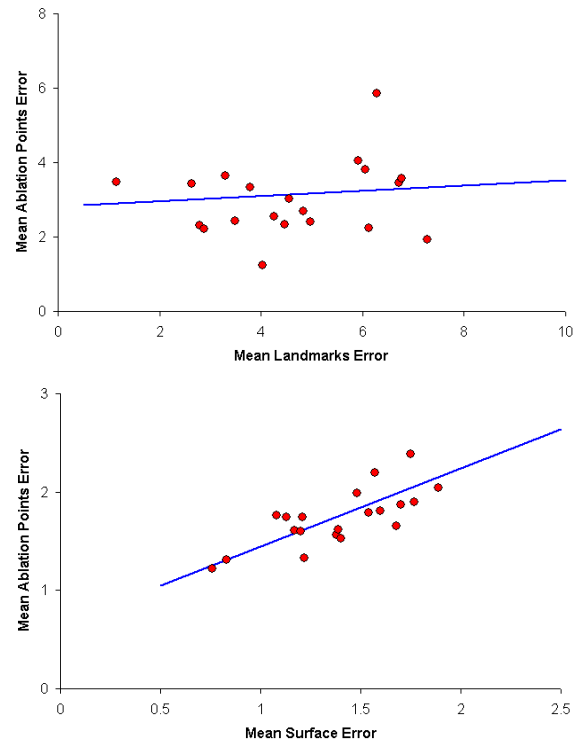


Figure 3 and 4. Regression line between mean landmarks error and mean ablation-point error. Regression line between mean surface error and mean ablation-point error.

## 4. Limitations and conclusions

### Limitations:

Various factors are involved in incorrect alignment: the movement of the patient's chest during respiration is not compensated for by the system [8]; as the CT/MRI image is not acquired on the same day as the procedure,

the atrial volume may differ [5], and using an irrigated ablation catheter could create a difference in left atrial volume during the procedure. Moreover, the atrial rhythm could differ between the day of CT/MRI image acquisition and the day of the ablation procedure; this circumstance did not compromise the results of registration [9].

**Conclusion:**

Mathematical results combined with ICE-guided validation reveal that local ICE-guided surface registration appears to perform better than landmarks registration. The fact that the ablation point-to-CT image distance was greater than the surface point-to-CT image distance ( $1.73 \pm 0.29$  mm vs.  $1.39 \pm 0.31$  mm) was, in our opinion, probably due to the different pressure applied to the mapping catheter in the ablation phase, to the edema generated along with the lesions, and to the amount of liquid infused during ablation by means of an irrigated catheter, which could change the shape of the chamber.

Local ICE-guided surface registration synchronizes acquired points on 3 continuous lines (figure 2). The number of points is balanced between left and right veins and acquired in locations where the catheter tip does not deform the chamber.

Our technique reduces the limitations of both strategies (surface and landmarks registration), facilitates the ablation procedure and reduces operator subjectivity, improving the reproducibility of registration.

**References**

[1] Mikaelian BJ, Malchano ZJ, Neuzil P, Weichet J, Doshi SK, Ruskin JN, Reddy VY. Images in cardiovascular medicine. Integration of 3-dimensional cardiac computed tomography images with real-time electroanatomic mapping to guide catheter ablation of atrial fibrillation. *Circulation*. 2005;112:e35-6.

[2] Tops LF, Bax JJ, Zeppenfeld K, Jongbloed MR, Lamb HJ, van der Wall EE, Schalij MJ. Fusion of multislice computed tomography imaging with three-dimensional electroanatomic mapping to guide radiofrequency catheter ablation procedures. *Heart Rhythm*. 2005;2:1076-81.

[3] Kistler PM, Rajappan K, Jahngir M, Earley MJ, Harris S, Abrams D, Gupta D, Liew R, Ellis S, Sporton SC, Schilling RJ. The impact of CT image integration into an electroanatomic mapping system on clinical outcomes of catheter ablation of atrial fibrillation. *J Cardiovasc Electrophysiol*. 2006;17:1093-101.

[4] Rotter M, Takahashi Y, Sanders P, Haïssaguerre M, Jaïs P, Hsu LF, Sacher F, Pasquié JL, Clementy J, Hocini M. Reduction of fluoroscopy exposure and procedure duration during ablation of atrial fibrillation using a novel anatomical navigation system *EurHeartJ*. 2005;26:1415-21.

[5] Zhong H, Lacomis JM, Schwartzman D. On the accuracy of CartoMerge for guiding posterior left atrial ablation in man. *Heart Rhythm*. 2007;4:595-602.

[6] Fahmy TS, Mlcochova H, Wazni OM, Patel D, Cihak R, Kanj M, Beheiry S, Burkhardt JD, Dresing T, Hao S,

Tchou P, Kautzner J, Schweikert RA, Arruda M, Saliba W, Natale A. Intracardiac echo-guided image integration: optimizing strategies for registration. *J Cardiovasc Electrophysiol*. 2007;18:276-82.

[7] Kanj MH, Wazni O, Fahmy T, Thal S, Patel D, Elay C, Di Biase L, Arruda M, Saliba W, Schweikert RA, Cummings JE, Burkhardt JD, Martin DO, Pelargonio G, Dello Russo A, Casella M, Santarelli P, Potenza D, Fanelli R, Massaro R, Forleo G, Natale A. Pulmonary vein antral isolation using an open irrigation ablation catheter for the treatment of atrial fibrillation: a randomized pilot study. *J Am Coll Cardiol*. 2007;49:1634-41.

[8] Noseworthy PA, Malchano ZJ, Ahmed J, Holmvang G, Ruskin JN, Reddy VY. The impact of respiration on left atrial and pulmonary venous anatomy: implications for image-guided intervention. *Heart Rhythm*. 2005;2:1173-8.

[9] Martinek M, Nesser HJ, Aichinger J, Boehm G, Purerfellner H. Accuracy of integration of multislice computed tomography imaging into three-dimensional electroanatomic mapping for real-time guided radiofrequency ablation of left atrial fibrillation-influence of heart rhythm and radiofrequency lesions. *J Interv Card Electrophysiol*. 2006;17:85-92.

[10] Daccarret M, Segerson NM, Gunther J, Nolker G, Gutleben K, Brachmann J, Marrouche NF. Blinded correlation study of three-dimensional electro-anatomical image integration and phased array intra-cardiac echocardiography for left atrial mapping. *Europace* (2007) 9, 923-926.

[11] Patel MP, Heist EK, Chevalier J, Holmvang G, D'Avila A, Mela T, Ruskin JN, Mansour MC. Effect of presenting rhythm on image integration to direct catheter ablation of atrial fibrillation. *J Interv Card Electrophysiol* (2008) 22:205-210.

[12] Nollo G, Cristoforetti A, Faes L, Centonze M, Del Greco M, Antolini R, Ravelli F. Registration and fusion of segmented left atrium CT Images with Carto Electrical maps for the ablative treatment of atrial fibrillation. *Computers in Cardiology* 2004;31:345-348.

[13] Cristoforetti A, Mase` M, Faes L, Centonze M, Del Greco M, Antolini R, Nollo G, Ravelli F. A stochastic approach for automatic registration and fusion of left atrial electroanatomic maps with 3D CT anatomical images. *Phys. Med. Biol.* 52 (2007) 6323-6337.

[14] Besi PJ, McKay ND. A method for registration of 3D shapes. *IEEE transactions on Pattern Analysis and Machine Intelligence* (1992) 14:239-256.

Stefano Indiani  
 Unità di Cardiologia, Ospedale dell'Angelo  
 Via Paccagnella 30174 Mestre (VE) Italy  
[Stefano.Indiani@gmail.com](mailto:Stefano.Indiani@gmail.com)