MEDINFO 2007
HISA Ltd Australia
© 2007 The authors. All rights reserved.

Identifying Visually Lossless Image Compression Levels For A Regional Scale Digital Radiological Image Distribution

WN Wong[a], NT Cheung[a], ACH Sek[a], V Fung[a], A Tong[a], William Chan[b], Amber Lam[b], CP Wong[c]

[a] *Health Informatics Section, Hong Kong Hospital Authority, HKSAR*
[b] *Information Technology Department, Hong Kong Hospital Authority, HKSAR*
[c] *Clinical Informatics Program Executive Group, Hospital Authority, HKSAR*

Abstract

This experimental study determined visually lossless image compression levels for 3 common digital radiological image modalities: Xrays, computerized tomography (CT) and magnetic resonance imaging (MRI). Compressed images of 17 different radiological pictures using JPEG lossy compression algorithm at different compression quality factors were rated by 160 clinicians from various clinical specialties using original-revealed side-by-side comparison method. Image quality of each testing image was rated as compared with the original image. The visually lossless compression level of each testing image was identified by the threshold of visible image quality deterioration. This study demonstrated that most radiological images could be moderately compressed with image quality well preserved. Visually lossless image compression levels for different image modalities were: Xray: Q10 (1:34-1:89); MRI: Q50-40 (1:6-1:14); CT: Q80-50 (1:8-1:13). The knowledge of visually lossless compression helps to reduce the data volume and network loading, which were critical for effective enterprise-wide radiological image distribution.

Keywords:

compression ratio, visually lossless,
image compression, JPEG, PACS

Introduction

Image compression has been advocated for effective large scale PACS implementation [1-2]. This study aimed at identifying the visually lossless image compression levels of three common radiological image modalities using JPEG compression.

Methods

This study evaluated the image quality of 17 radiological images including 6 Xrays (2 PA Chest Xray; 2 Lateral lumbosacral spine Xray; 2 AP abdominal Xray), 7 computerized tomography (CT) (2 Horizontal slice CT brain; 2 Horizontal slice CT thorax, 3 Horizontal slice CT abdomen) and 4 magnetic resonance imaging (MRI), 3 Horizontal slice MRI brain; 1 Saggital slice MRI spinal cord) at different JPEG (12-bit) compression ratios in a clinical environment by 160 clinicians from different specialties. Image quality of each compressed image was evaluated by original-revealed side-by-side comparison method [3]. Relative image quality of each testing image as compared to the "original" image was rated on a 4 point scale (3=no visible difference; 2= slightly poor; 1=moderately poor; 0=significantly poor). The image evaluation interface is shown in Figure 1. The mean image quality score of each was calculated. Any difference in the image quality between the original and testing image was identified by ANOVA post hoc analysis. Visually lossless image compression levels of various image modalities were identified by comparing the relative image quality of images compressed at different compression levels and identifying the thresholds of visible image quality deterioration.

Results

Relative image quality of different image at different compression levels are presented in Figures 2 to 4**.**

For Xrays, the difference of image quality was not statistically significant even up to maximum compression of Q10 quality factor (p=0.35-1.0) with a corresponding compression ratio of 1:32-1:89. For MRI, the image quality of images was maintained until reaching Q10-Q20 quality factor with compression ratio 1:7-1:18 ($p<0.001$). The image quality of all CT images dropped significantly past compression Q30-Q70 ($p<0.001$-0.02) with compression ratio 1:9-1:14.

Visually lossless image compression level thresholds for different image modalities were: Xray: Q10 (1:32-1:89); MRI: Q30(1:6-1:12); CT: Q80 (1:7)

Discussion

Clinically acceptable compression levels have been the focus of many studies worldwide. It has been shown that image quality deterioration can be tolerated without affecting diagnostic accuracy [4]. Similar studies using receiver

operating characteristic analysis have shown that diagnostic performance can be well preserved despite noticeable compression artifacts [5-8]. Although high level of compression could allow substantial cost savings, it has seldom been applied in real clinically situations and the presence of perceivable artifact reduces acceptance amongst skeptical clinicians and radiologists. In this study, another approach was adopted to determine more conservative thresholds - "visually lossless" compression levels. Although the identified visually lossless compression ratios were dependent on the images selected and the image viewing condition, monitor grade and size, they provide practical information for applying image compression in clinical settings.

Conclusion

Most radiological images could be moderately compressed with image quality well preserved. The knowledge of the visually lossless image compression of various images allows a great reduction in data volume and network loading to an affordable level for effective image distribution on a regional based network

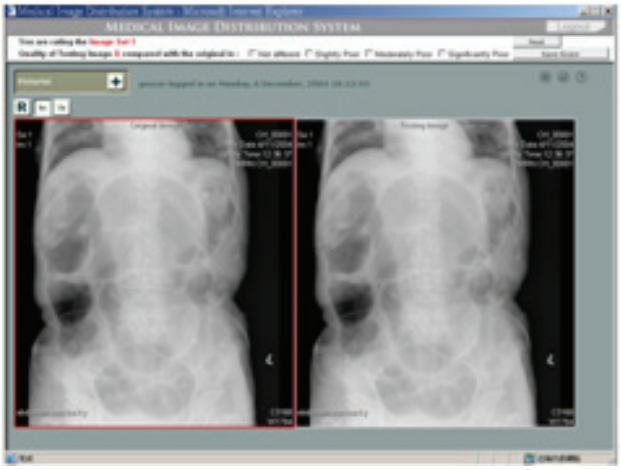

Figure 1 - Showed the image web browser for image quality evaluation. Original uncompressed image was shown on the left while testing image on the right



Figure 2 - Showed the image quality of Xrays, CT scans and MRI scans at different quality factor compressions. Image quality of different testing images compressed at different quality factors was evaluated on 4 points scale (3=not different, 2=slightly poor, 1=moderately poor and 0=significantly poor)

References

[1] Hung HK. PACS and Imaging Informatics – Basic Principles and Applications. John Wiley & Sons. Inc. 2004

[2] Kahn MG. Enterprise-wide clinical data integration. Information networks for community health. New York, NY:Springer-Verlag 1997; p 41-45

[3] Slone RM, Foos DH, Whiting BR, et al. Assessment of visually lossless irreversible image compression of three methods by using an image-comparison workstation. Radiology 2000, 215:543-553.

[4] Terae S, Miyasaka K, Kudoh K et al. Wavelet compression on detection of brain lesions with magnetic resonance imaging. 2000; vol 13, 4: 178-190

[5] Zheng LM, Sone S, Itani Y et al. Effect of CT digital image compression on detection of coronary artery calcification. 2000; 41: 116-121

[6] Powell KA. Clinical Evaluation of wavelet-compressed digitized screen-film mammography. 2000; 7: 311-316

[7] Megibow AJ, Rusinek H, Lisi V et al. Computed tomography diagnosis utilizing compressed image data: an ROC curve analysis using acute appendicitis as a model. 2002; vol 15, 2: 84-90

[8] Kotter E, Roesner A, Winterer JT et al. Evaluation of lossy data compression of chest Xrays – A receiver operating characteristic study. 2003; vole 38, 5: 243-249